

Original Article

A morphological Study of Anatomical Variations of Frontal Sinus in Adult Libyan People Using CT Scan

Asil. A .Almasheety¹, Mustafa A Karwad^{1*}, Murshed H. Haidar²

1.Department of Clinical Anatomy, Faculty of Applied Medical Sciences, LIMU.

1*Department of Anatomy, Faculty of Medicine, University of Benghazi / Faculty of AMS, LIMU.

2.Department of Radiology, Faculty of Medicine, University of Benghazi / Faculty of AMS, LIMU.

Mustafa.karwad@uob.edu.ly

Abstract:

Background: The structure of the frontal sinus varies greatly, and these differences influence the onset and progression of clinical diseases. Frontal sinus morphology is unique to each individual and may be used to properly identify people.

Aim: The aim of this study is to evaluate the morphometric anatomical variations of the frontal sinus in adult Libyan people using a CT scan in relation to gender.

Method and result: 147 patients (78 females and 69 males) were included in this study. Patients were divided into three groups regarding their frontal sinus pneumatization extent on the orbital roof: group 1 pneumatization (small), group 2 pneumatization (medium), and group 3 pneumatization (large).

We found that the most common frontal sinus type is medium-sized (37.75 %), followed by the small (24.8%) and large (22.8%) types, respectively. There was no significant difference between the right and left sides in terms of frontal sinus type (P-value = 0,311). We recorded aplasia in 17.7% of all patients, which included (bilateral in 9.5%, left unilateral in 2% and right unilateral in 6.1%).

In conclusion, we classified frontal sinuses using the categorization established by Stokovic et al. and showed that pneumatization patterns differ even between two opposite sides of the same individual.

Citation. A Karwad. Mustafa , 1. A morphological Study of Anatomical Variations of Frontal Sinus in Adult Libyan People Using CT Scan

<https://doi.org/10.54361/ljmr.17-18>

Received: 12/04/23accepted: 30/04/23; published: 30/06/23Copyright ©Libyan Journal of Medical Research (LJMR) 2023. Open Access. Some rights reserved. This work is available under the CC BY license <https://creativecommons.org/licenses/by-nc-sa/3.0/ig>

Introduction:

The frontal sinus (sinus frontalis) is one of the paranasal sinuses. The majority of the seats are located in the frontal squamous region. It is the bone in the posterior section of the superciliary arches that connects the outer and inner tables; it opens into the adjacent nasal cavity's lateral wall by opening into the middle meates.^{1,2}

The frontal, maxillary, ethmoid, and sphenoid sinuses are four paired sinuses, and each of their developmental processes is unique.³

The frontal sinuses (FS) are pairs of pneumatic cavities that develop gradually and are not present at birth. Primary pneumatization of the frontal bone occurs slowly during the first year of life.⁴

The FS is supposed to be an extension of the anterior ethmoid cell and develops the most after birth. Rapid pneumatization occurs 2 years from the initiation of sequestering pneumatosis until puberty, and the FS is apparent on computed tomography after about 3 years. Pneumatization of the FS begins at the age of 8 years and continues till the age of 18 to 20 years.^{4,5} They are rarely symmetrical; the two sinus cavities are separated by a septum is frequently deviated from the midline, are usually asymmetrical, and both extend back into the orbital portion of the frontal bone.⁶⁻⁸

Frontal sinuses are one of the human body's most variable anatomic structures. By direct observation, the anatomical variations in their size and location may reflect the pathology of the anatomically related areas.^{1,9}

The FS has no commonly recognized anatomical classification. Previous

research on anatomic variations defined volumetric variants of the frontal sinus using labels such as aplasia, hypoplasia, medium-size, and hyperplasia, which were only based on two-dimensional assessments. Two-dimensional in this way, the 'width' and 'height' parameters define the pneumatization pattern.^{8,10,11}

Stokovic et al. (2018) have revealed a strong association between coronal plane measurements of frontal sinus size parameters and the amount of frontal sinus-orbital roof contact area. Moreover, they identified three types of frontal sinuses based on size and relationship to the orbital cavity using cluster analysis.¹²

This is an uncomplicated classification. This allows the frontal sinus type to be easily identified on a standard sinus radiograph and has the potential to be highly useful in the clinical setting if it is found to be strongly associated with the progression of pathological conditions.¹²

The aim: to evaluate the morphometric anatomical variations of the frontal sinus in adult Libyan people using a CT scan in relation to gender.

Methodology:

This retrospective study included 147 (69 males and 78 females) subjects randomly selected from Benghazi hospitals, after 11 subjects were excluded from the 158 who had a CT scan of their paranasal sinuses between May 2020 and March 2021, with ages ranging from 18 to 80. Exclusion criteria include the presence of pathological features or fractures in the entrance area, as well as imaging

quality that was inadequate or inappropriate for CT cuts and children. The DICOM viewer for medical image software is used to classify the frontal sinus into three groups based on their

pneumatization extent on the orbital roof as proposed by Stokovic et al.¹² We subdivided the orbital roof into three parts and classified it as shown in figure 1.

Fig. 2 Coronal computed tomography images showing the small (a), medium (b), and large (c) categories of frontal sinuses in relation to the orbital roof.

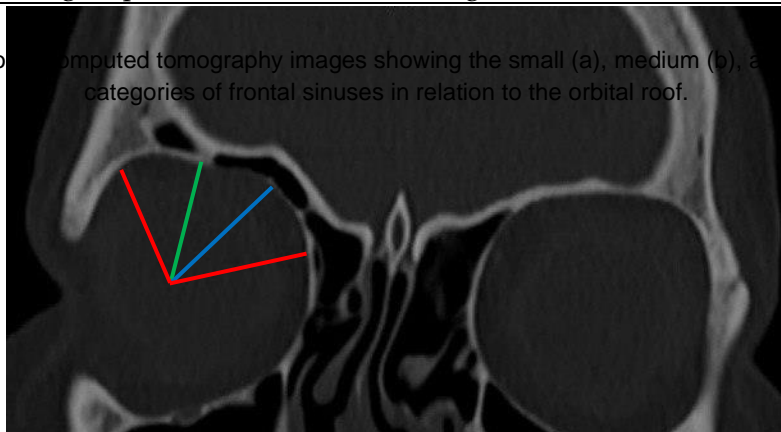
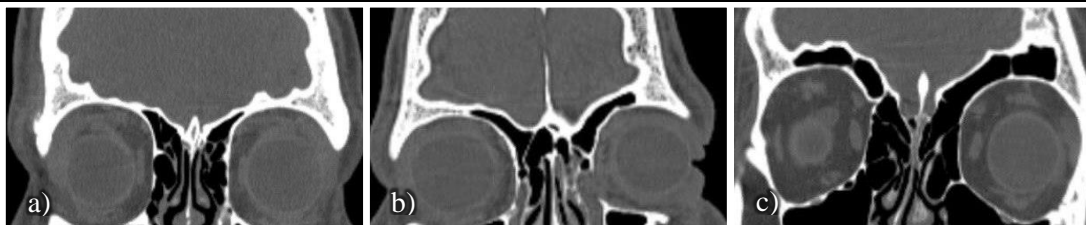

Fig. 1: Coronal computed tomography image illustrating the three-part segmentation of the orbital roof. The space between the two red, blue, and green lines represents the medial, central, and lateral parts of the roof, respectively.

Group 1 pneumatization (small): no or minimal pneumatization in the orbital roof's medial part. (fig. 2a)

Group 2 pneumatization (medium): pneumatization of the medial and central parts of the orbital roof. (fig. 2b)

Group 3 pneumatization (large): pneumatization of the entire orbital roof (medial, central, and lateral). (fig. 2c)



The Statistical Package for Social Sciences Windows (SPSS) software version 26 was used to perform statistical analyses on all the data obtained. The results were evaluated with 95% confidence intervals, and $P < 0.05$ was considered statistically significant. Means, standard deviations, and minimum and maximum values were calculated for quantitative variables based on CT-

based morphometric analyses of the FSs.

Results:

In this study, 147 subjects had a frequency of aplasia (17.7%), as shown in table 1. The results showed three female subjects (11.6%) only had unilateral absence of sinus on the left side; five females and four males (34.6%) had unilateral absence on the

right side; eight females and six males (53.8%) had bilateral aplasia.

The frequency and distribution of aplasia are shown in figure 3.

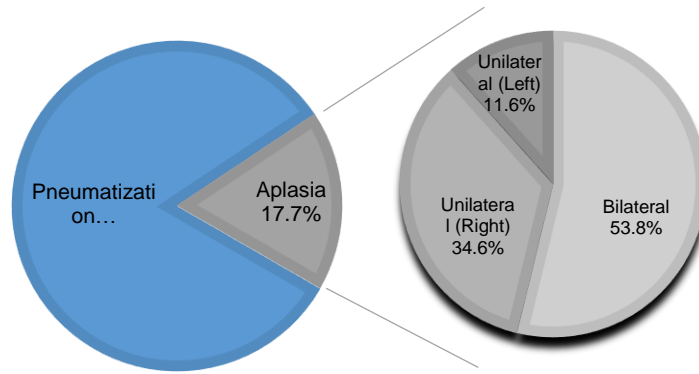


Table 1: The findings show the frequency of aplasia in 147 subjects.

	Bilateral	left unilateral	right unilateral
	N / P%	N / P%	N / P%
Male	6 / 4.1	0	4 / 2.7
Female	8 / 5.4	3 / 2.0	5 / 3.4
Total	14 / 9.5%	3 / 2%	9 / 6.1%

N=number, P=present

The findings in terms of the frequency sized, second to the small (24.8%) and

Fig. 3 Shows the percentage of anatomic variations of the frontal sinus.

of sinus types are summarized in Table 2. The most prevalent frontal sinus type (37.75 %) was shown to be medium-

large (22.8%) types.

Table 2: The findings recorded the frontal sinus type in 147 participants.

Type of frontal sinus	Number	Frequency %
Right		
Aplasia	25	17

Small	33	22.4
Medium	60	40.8
Large	29	19.7
Left		
Aplasia	18	12.2
Small	40	27.2
Medium	51	34.7
Large	38	25.9

As demonstrated in table 3, there was no significant difference in frontal

sinus type between the right and left sides after the aplasia was excluded

Table 3: Comparison of the prevalence of frontal sinus types on the right and left sides.

	Right frontal sinus			
	Small	Medium	Large	Total
	N / P%	N / P%	N / P%	N / P%
Left frontal sinus				
Small	17 /54.84	13 /22.03	7 /24.14	37/31.09
Medium	7/22.58	24 /40.68	14/48.28	45/37.81
Large	7 /22.58	22/37.29	8/27,59	37/31.09
Total	31 /100	59 /100	29 /100	119/100

P=0,311; McNemar-Bowker Test
Using the T-test, the descriptive statistics, mean values, standard deviation, and P value are shown in table 4. Males generally have a higher mean value for all variables than females. The standard right length in males was 8.174mm and 7.139mm in females, while the left length in males was 8.462mm and 7.928mm in females. The difference in right length between males and females was found to be statistically significant (P value 0.032),

but the opposite was not (P value 0.335). Males had an average right width of 21.484mm, while females had an average right width of 21.889mm. Males had a mean left width of 23.663mm while females had a mean left width of 21.984mm. The difference in left width among males and females was found to be statistically significant (P value 0.03). The difference in width between the right and left sides was not statistically significant. (P value = 0.779, P = 0.308).

Table 4: presents a simple statistical analysis of Frontal Sinus type by different variable and gender.

Variable	Gender	Mean	Stander deviation	p-value
Right length	Male	8.174	2.688	0.032
	Female	7.139	2.416	
Left length	Male	8.462	2.878	0.335

	Female	7.928	3.083	
Right width	Male	21.484	7.131	0.779
	Female	21.889	8.486	
Left width	Male	23.663	8.836	0.308
	Female	21.984	8.849	

The basic measurements of the anatomical variants of the three groups of the frontal sinus are summarized in Table 5.

There were minor variations between the right and left sinuses (all mean values varied by 1.93mm).

In this research, the medium sinus had a maximum length ranging from (12.700mm in the left to 13.569mm in

the right), as well as maximum width (of 29.814mm in the right to 30.409 mm in the left) . In addition to this, the confined interval for the length ranged from (8.018 - 9.307mm) in the left to (7.170 - 8.486mm) in the right, while the width ranged from (22.659 - 25.034mm) in the left to (20.964 - 22.868mm) to the right.

Table 5: statistical analysis of the Frontal Sinus type.

Type	Variable	Mean	SD	Minimum	Maximum	95%confined interval Upper / lower
Small	LL	5.955	2.549	1.020	12.676	6.805/5.105
	LR	5.989	1.941	2.486	10.575	6.701/5.277
	LW	12.263	2.594	6.022	16.916	13.128/11.398
	RW	12.454	3.080	6.637	19.800	13.584/11.324
Medium	LL	8.663	2.145	4.260	12.700	9.307/8.018
	LR	7.828	2.525	3.020	13.569	8.486/7.170
	LW	23.847	3.952	9.790	30.409	25.034/22.659
	RW	21.917	3.650	15.590	29.814	22.868/20.965
Large	LL	10.017	2.830	4.960	16.465	10.974/9.060
	LR	9.399	2.302	5.120	13.084	10.292/8.507
	LW	32.726	3.852	27.428	43.450	34.029/31.423
	RW	31.323	5.016	20.479	47.151	33.268/29.378

LW=left width, RW=Right width, LL=left length, RL=right length ,SD=stander deviation

Discussion:

The total prevalence of aplasia in this research was 17.7%, as seen in figures 1 and 4, whereas bilateral absence of the frontal sinus was 9.5% (4.1% for males and 5.4% for females), as indicated in table 1.

Schuller observed that a bilateral absence of the frontal sinuses in adults

may be seen in around 5% of all radiographs.¹³ The bilateral absence of a frontal sinus was identified in 10% of samples, according to Leicher's definition.¹⁴ Yoshino et al. discovered the absence of a sinus in 4.8% of male samples in a research on Japanese adult skulls.¹⁵

The following populations were found to have a bilateral absence of the frontal

sinuses: Alaskan Eskimos account for 25% of males and 36% of females.¹⁶ Bushmen account 11% of males and 11% of females, while Awarischs account 8% of males and 13% of females.¹⁴

Furthermore, the Japanese make up 13% of males and 23% of females.¹⁷ Canadian Eskimos account for 43% of males and 40% of females,¹⁸ while Austrians account for 10% of males and 10% of females¹⁹; additionally, Germans,²⁰ 3.4%, and Turks,²¹ account for 3.1% in males and 5.1% in female.

According to the literature, the prevalence of bilateral absence of the frontal sinuses in this research was lower than that reported for other ethnic communities and was comparable to that of the German and Turkish populations. Further, these studies show a higher incidence among females than males, which is consistent with our findings.

Frontal sinus is absent on one side alone, as shown in figures 1 and 4. The

frequency of right unilateral frontal sinus absence was 2.7% in males and 3.4% in females in this research. Males had 0% left unilateral sinus absence and females had 2%, as shown in table 1. Yoshino et al. found that 14.3% of males (9.5% right, 4.8% left) and 7.1% of females (7.1% right, 0.0% left) had unilateral sinus absence.¹⁴

Nowak and Mehls (1977) found a unilateral absence of the frontal sinus in 7.4% of adults, 4.2% on the right and 3.2% on the left (in 3.6% of males and 2.8% of females).²⁰

Schuller reported a 1% frequency of unilateral absence, 0.8% of right unilateral aplasia in males and 2% in females, and 1.1% of left unilateral aplasia in males and 0.9% in females in Turkish populations.¹³

Furthermore, Tatsumak reports, the frequency of unilateral aplasia was 1.33% (1% right, 0.33% left),²² Aydinoglu reports 4.8% (2.83% right, 2% left),²¹ and Cakur 1.22% (0.73% right, 0.33% left).²³

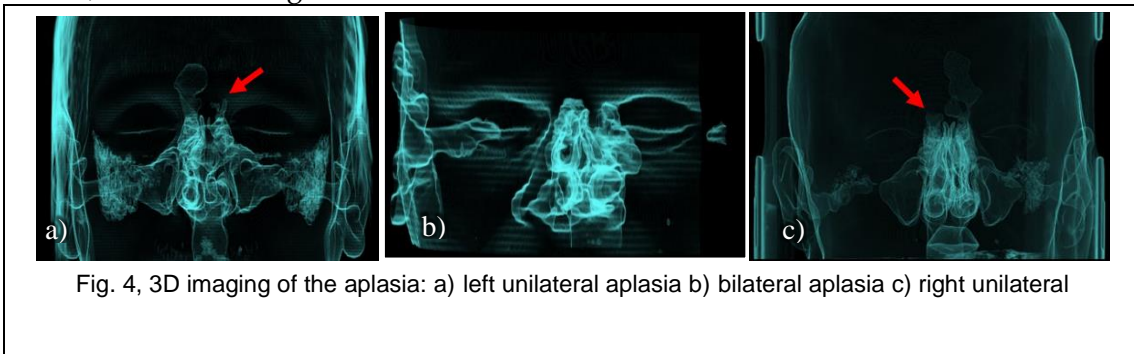


Fig. 4, 3D imaging of the aplasia: a) left unilateral aplasia b) bilateral aplasia c) right unilateral

According to the findings, frontal sinuses may be classified into three categories based on the extent of pneumatization of the orbital roof as evaluated by conventional clinical radiological examination, according to Stokovic et al.¹² (small, medium-sized, and large).

According to table 2, the most prevalent type in our sample was

medium-sized, followed by small, and lastly, larger size, which is consistent with previous research by Zdemir et al.²⁴

In addition to that, contrary to (Guerram et al.,²⁰ Yuksel Aslier et al.,⁸ and Stokovic et al.¹²) that showed that the most common type is medium-sized, followed by large, and the last is small.

All of the response variables demonstrated that the mean value is consistently greater in males than in females, and the sinus is higher in males than in females, as shown in table 3. It can be linked to the fact that morphological variations in the cranium between sexes are primarily determined by genetic causes, more so by dietary, hormonal, or muscular causes.²⁵ these factors explain why males have a larger frontal sinus than females.

The left frontal sinus is significantly larger than the right side in both males and females, which is similar to the results of Camargo et al.,²⁶ Pondé et al.,²⁷ and Shireen et al.²⁸ but differs from the findings of Kotrashetti et al.²⁹ One side is larger than the other due to their independent formation.^{29,30} One sinus may be larger than the other, with the larger sinus crossing the midline and even overflowing the smaller.²¹

All of the response variables for the three types of sinuses are illustrated in table 5, with the average mean of the left length being 5.955mm, 8.633mm, and 10.017 in small, medium, and large sizes, respectively, compared with the average mean of the right length, which was 5.989mm, 7.828mm, and 9.399mm in small, medium, and large sizes, respectively. Additionally, the average

mean of the left width found was 12.263mm, 23.847mm, and 32.726mm in small, medium, and large sizes, respectively, compared with the average mean of the left width, which was 12.454mm, 21.917mm, and 31.323mm, respectively. All evidence points to the left large sinus having a mean greater than the right large sinus, and that is similar to the left medium-size sinus but contrasted with the left small sinus.

The results of the current study will influence a discussion on volumetric diagnosis for frontal sinus pneumatization pattern categorization. It will also help to advance radiology understanding, which may be utilized to create computerized models for creating newer surgical procedures and guidance techniques for frontal sinus operations.

Conclusion:

In conclusion, we classified frontal sinuses using the categorization established by Stokovic et al. and showed that pneumatization patterns differ even between two opposite sides of the same individual. The more frequent type of the frontal sinus is the medium-sized. This study's findings could be used to illustrate the clinical benefit of this categorization.

References:

1. Drake R, Vogl W, Mitchell A. *Gray's Anatomy For Students*. 4th ed.; :1064.
2. Guerram A, Le Minor JM, Renger S, Bierry G. Brief communication: The size of the human frontal sinuses in adults presenting complete persistence of the metopic suture. *Am J Phys Anthropol*. 2014;154(4):621-627.
3. Al-Balas HI, Nuseir A, Alzoubi F, et al. Prevalence of frontal sinus aplasia in Jordanian individuals. *J Craniofac Surg*. 2020;31(7):2040-2042.
4. Baumgartner EA, Louis S. the Development OF the Hypophysis IN. *Anat Rec*. 1918;15(2):73-92.

5. Aslier NGY, Zeybek G, Karabay N, et al. The Relationships Between Craniofacial Structure and Frontal Sinus Morphology: Evaluation With Conventional Anthropometry and CT-Based Volumetry. *Ear, Nose Throat J.* 2020;99(10):637-647.
6. Sinnatamby CS Last RJ. *Last's Anatomy : Regional and Applied.* 10th ed. Edinburgh: Churchill Livingstone; 1999.
7. Moore K, Dalley A, Agur A. *Clinically Oriented Anatomy.* 7th ed.; :961.
8. Yüksel Aslier NG, Karabay N, Zeybek G, et al. Computed tomographic analysis: The effects of frontal recess morphology and the presence of anatomical variations on frontal sinus pneumatization. *J Craniofac Surg.* 2017;28(1):256-261.
9. Harris AM, Wood RE, Nortjé CJ, Thomas CJ. The frontal sinus: forensic fingerprint? A pilot study. *J Forensic Odontostomatol.* 1987;5(1):9-15.
10. Song X, Zhao B, Wang C, Wang N. Dynamic Response of the Skull with Sinuses under Blunt Frontal Impact: A Three-Dimensional Computational Study. *Comput Math Methods Med.* 2015;2015:848079.
11. Gotlib T, Kuźmińska M, Held-Ziółkowska M, Osuch-Wójcikiewicz E, Niemczyk K. Hidden unilateral aplasia of the frontal sinus: a radioanatomic study. *Int Forum Allergy Rhinol.* 2015;5(5):441-444.
12. Štoković N, Trkulja V, Čuković-Bagić I, Lauc T, Grgurević L. Anatomical variations of the frontal sinus and its relationship with the orbital cavity. *Clin Anat.* 2018;31(4):576-582.
13. Schuller A. Note on the identification of skulls by X-ray pictures of the frontal sinuses. *Med J Aust* 1943;1:554-6
14. Szilvassy J. Die Stirnhöhlen der Schadel aus dem awarischen Graberfeld von Zwolfaxing in Niedero sterreich. *Ann Naturhist Mus Wien* 1974;78:109-18
15. Yoshino M, Miyasaka S, Sato H, Seta S. Classification system of frontal sinus patterns by radiography. Its application to identification of unknown skeletal remains. *Forensic Sci Int.* 1987;34(4):289-299. doi:10.1016/0379-0738(87)90041-7
16. Koertvelyessy T. Relationships between the frontal sinus and climatic conditions: a skeletal approach to cold adaptation. *Am J Phys Anthropol.* 1972;37(2):161-172. doi:10.1002/ajpa.1330370202
17. Ikeda J. Interpopulation variations of the frontal sinus measurements: comparison between the Jomon and recent Japanese population. *J Anthropol Soc Nippon Suppl* 1980;90:91-104
18. Hanson CL, Owsley DW. Frontal sinus size in Eskimo populations. *Am J Phys Anthropol.* 1980;53(2):251-255.
19. Szilvassy J. Zur Variation, Entwicklung und Vererbung der Stirnhöhlen. *Ann Naturhist Mus Wien* 1982;84A: 97-125
20. Nowak R, Mehls G. Die aplasien der sinus maxillares und frontales unter besonderer Berücksichtigung der pneumatisation bei spalttragern. *Anat Anz* 1977;142: 441-50
21. Aydinlioğlu A, Kavakli A, Erdem S. Absence of frontal sinus in Turkish

- individuals. *Yonsei Med J.* 2003;44(2):215-218.
22. Tatlisumak E, Ovali GY, Asirdizer M, et al. CT study on morphometry of frontal sinus. *Clin Anat.* 2008;21(4):287-293.
23. Çakur B, Sumbullu MA, Durna NB. Aplasia and agenesis of the frontal sinus in Turkish individuals: a retrospective study using dental volumetric tomography. *Int J Med Sci.* 2011;8(3):278-282.
24. Özdemir M, Kavak RP, Öcal B, Soysal H. A novel anatomical classification of the frontal sinus: can it be useful in clinical approach to frontal sinusitis? *Egypt J Otolaryngol.* 2021;37(1).
25. Uthman AT, Al-Rawi NH, Al-Naaimi AS, Tawfeeq AS, Suhail EH. Evaluation of frontal sinus and skull measurements using spiral CT scanning: an aid in unknown person identification. *Forensic Sci Int.* 2010;197(1-3):124.e1-124.e1247.
26. Camargo JR, Daruge E, Prado FB, et al. The frontal sinus morphology in radiographs of Brazilian subjects: Its forensic importance. *Brazilian J Morphol Sci.* 2007;24(4):239-243.
27. Pondé JM, Nonato Andrade R, Maldonado Via J, Metzger P, Teles AC. Anatomical Variations of the Frontal Sinus. *Int J Morphol.* 2008;26(4):803-808.
28. Shireen A, Goel S, Ahmed IM, Sabeh AM, Mahmoud W. Radiomorphometric Evaluation of the Frontal Sinus in Relation to Age and Gender in Saudi Population. *J Int Soc Prev Community Dent.* 2019;9(6):584-596.
29. Belaldavar C, Kotrashetti VS, Hallikerimath SR, Kale AD. Assessment of frontal sinus dimensions to determine sexual dimorphism among Indian adults. *J Forensic Dent Sci.* 2014;6(1):25-30.
30. Nambiar P, Naidu MD, Subramaniam K. Anatomical variability of the frontal sinuses and their application in forensic identification. *Clin Anat.* 1999;12(1):16-19.